

Motion-onset and pattern-reversal VEPs in diagnostics of Neuroborreliosis

Kubová Z, Szanyi J, Langrová J, Kremláček J, Kuba M, Honegr K.¹

Department of Pathophysiology, Charles University - Faculty of Medicine in Hradec Králové
and ¹Department of Infectious diseases, Faculty Hospital in Hradec Králové, Czech Republic

Zuzana Kubová, MD, PhD
Department of Pathophysiology
Faculty of Medicine
Simkova 870
500 38 Hradec Králové
Czech Republic

Tel.: +420 49 5816 391
Fax: +420 49 5513 597
E-mail: kubova@lfhk.cuni.cz

Running title: VEP diagnostics of neuroborreliosis

Abstract

Introduction: Neuroborreliosis (NB) is a form of Borreliosis that affects central and/or peripheral nervous system. Although it can mimic a lot of neurological and ophthalmologic disorders including e.g. Multiple Sclerosis and Optic Neuritis, visual evoked potential (VEP) examination is usually not used in NB diagnostics. **Methods:** Combined VEP testing (pattern-reversal VEPs and two types of motion-onset VEPs (M-VEPs) to linear and radial motion) was performed in 81 patients with NB verified by laboratory results - positive PCR or intrathecal antibodies production. 34 patients reported diplopia or blurred vision related to Borreliosis.

Results: In 33 (40%) patients the VEPs were delayed: M-VEPs were pathological in 22 (27%) patients, reversal VEPs in 5 (6%) patients and both VEP types in 6 (7%) patients.

Conclusions: Our findings suggest that the VEP testing (especially the M-VEPs) can confirm the CNS involvement. Much higher sensitivity of M-VEPs in comparison with reversal VEPs can result from rather selective (earlier) involvement of the magnocellular pathway or the dorsal stream.

Key words: Neuroborreliosis, VEP, visual evoked potentials, pattern-reversal, motion-onset.

Introduction

Neuroborreliosis (NB) is a form of Spirochetal infection Borreliosis (Lyme disease) that affects central or peripheral nervous system – it usually appears as an acute or chronic disorder in the second or third disease stage in about 1/5 of patients (Priem et al., 2003; Christova and Komitova, 2004). Clinical picture of NB includes symptoms of radiculitis/neuritis, meningitis, encephalitis and myelitis (e.g. Oschmann et al, 1998; Pal et al., 1998) or various psychiatric disorders (e.g. Schneider et al., 2002). Its diagnosis is usually based on a finding of lymphocytic pleocytosis in cerebrospinal fluid, serologic methods (presence of intrathecal antibodies production) or detection of specific DNA fragments by polymerase chain reaction (PCR) in the cerebrospinal fluid (Kaiser, 1998; Wilske et al., 2000), whilst cortical evoked potential testing is only rarely performed in these patients (Halperin et al, 1989, Chabot and Sigal, 1995; Gutierrez et al., 2001). This is rather surprising because NB can mimic many neurological and ophthalmologic disorders including e.g. Multiple Sclerosis (Dupuis, 1988; Karussis et al., 1999; Trojano and Paolicelli, 2001) and Optic Neuritis (Lesser et al., 1990; Karma et al., 1995), the diagnosis of which is frequently assessed by visual evoked potential (VEP) findings (McDonald et al. 2001). The shortage of sufficient literature data on eventual usefulness of VEPs in NB diagnostics led us to investigate VEPs in a group of patients with serologically confirmed Borreliosis (in 90 % of them NB was verified by other laboratory methods).

Methods:

Subjects

In the years 1998 through 2004 we investigated a total number of 81 patients (62 women and 19 men, mean age of 44 ± 13 years) with disseminated Lyme borreliosis (all were diagnosed at the Department of Infectious diseases, Faculty hospital in Hradec Králové), all were

seropositive. In all of them the diagnosis of Neuroborreliosis was set on basis of a clinical picture and of laboratory methods (presence of intrathecal antibodies production or detection of specific DNA fragments by polymerase chain reaction (PCR) in cerebrospinal fluid or MRI findings). Six patients were at the time of our examination in stage of early NB, the remaining 75 patients suffered from chronic NB. None of the patients suffered from any evident ophthalmologic disorder (in one case there was Optic neuritis in anamnesis) and their visual acuity was normal (eventually well corrected during the VEP examination). Nevertheless, 34 patients reported “non-specific” visual symptoms – they complained of transitory impaired, blurred or diplopic vision, pain or pressure behind eyes at the time of our examination. All these patients were seen by an ophthalmologist who did not find any particular eye disorder. All subjects were fully informed about the purpose and procedures of the study and then they provided voluntary written consent to participate. All procedures complied with the tenets of the Declaration of Helsinki and were pre-approved by the Ethical committee of our Faculty of Medicine and Faculty hospital for protection of human subjects.

VEP methods

Two types of visual stimuli were used for VEP eliciting – pattern-reversal and motion stimuli with the aim to test the function of the two fundamental subsystems of the visual pathway (the magno- and parvocellular ones) and their cortical projections (the dorsal and ventral streams). The first visual stimulation, activating predominantly the primary visual area V1, was pattern-reversal of black/white checkerboard with an element sizes of 40', 20' and 10' (with 96% contrast according to Michelson and frequency of 2 rev./s).

As the second type of stimulation we used two variants of monochromatic moving stimuli that are supposed to activate extrastriate visual areas (Kuba and Kubová, 1992; Kubová et al., 1995; Hollants-Gilhuijs et al., 2000):

1) translating (unidirectional linear) motion of low contrast (10%) structure of isolated checks (40' check size and 120' check-to-check distances). The pattern moved randomly in one of four fundamental directions with velocity of 10°/sec.

2) radial motion – randomly performed centrifugal or centripetal motion (“expansion/contraction”) of low contrast (10%) concentric circles with sinusoidal luminance modulation. The spatial frequency of structure decreased and motion velocity increased from the centre (fixation point) towards periphery respecting the size of the retinal receptive fields and sensitivity to motion velocity across the retina (Kremláček et al., 2004).

Both moving stimuli had the same timing – 200 ms of motion was followed by 1s interstimulus interval (stationary pattern).

All visual stimuli were generated (using VSG 2.5; CRS Ltd., UK) on the 21“Iyama monitor (Japan) with the vertical frequency of 105 Hz. The stimulus field subtended 37 x 28 deg in viewing distance of 0.5 m. The average luminance was 17 cd/m². Correct fixation of the stimulus field centre was monitored via infra-red CCD camera.

Recording and data analysis:

Standard recordings included pseudo-unipolar derivations (with the right ear lobe reference) from the midline O_Z, P_Z, C_Z and F_Z and also from O_L and O_R (5 cm to the left and right from the O_Z position). These lateral recording sites were used, since motion-onset specific peak (N160) in the motion-onset VEPs (M-VEPs) is usually lateralised (**irrespective to handedness of subjects**) towards the temporo-occipital cortex (Göpfert et al., 1988).

Maximal VEP amplitude was found in 60% of subjects in the right hemisphere and in 20% in the left hemisphere (Kubová et al., 1990). For further evaluation, the data from the occipital derivation with maximum response (i.e. with largest amplitude) were taken (O_Z in reversal VEPs and O_L or O_R in M-VEPs).

In the reversal VEPs we measured latencies of the main P100 peak and in the M-VEPs latencies of the N160 peak were evaluated (this peak was shown to represent the main motion specific component of this VEP type (Göpfert et al., 1983; Kuba and Kubová, 1992; Kubová et al., 1995; Hoffmann et al., 2001; Müller et al., 2004).

40 single responses (440 ms epochs with sampling frequency of 500 Hz) were averaged.

Although some people speculate about a theoretical possibility of M-VEPs contamination with pursuit eye movement artefacts (mainly in translational (unidirectional linear) motion stimuli), after repeated testing of EOG we can claim that this is not the case. Moreover, eventual eye movements do not cause potentials interfering with main peaks of the M-VEPs since they have different latency and localisation (Hoffman and Bach, 2002).

The resulting VEP values (from monocular recordings) were compared with “norms” acquired in our laboratory by testing of 47 normal subjects. The Table 1 shows the mean values of latencies and their SDs for all evaluated peaks (P100 of the pattern reversal VEP and N160 of the linear and radial motion-onset VEPs). The value of mean + 2.5 SD represented the upper limit of the norm for each type of VEP.

Insert Tab 1 about here

Results

In the group of 81 NB patients, the combined pattern-reversal and motion onset VEP examination confirmed CNS disorder in 33 (40%) of them (Fig 1A) – five patients (6%) displayed prolonged latencies only to reversal stimuli (either to all used check sizes or at least to one of them), 22 patients (27%) only to motion stimuli (either to both motion variants or at least to one of them) and six patients (7%) had abnormal latencies in VEPs both to reversal and motion stimulation.

When we compared the VEP results in patients reporting subjective vision disorders (blurred vision or diplopia) with VEPs in patients without any vision dysfunction (Fig. 1B, C), we found considerably higher occurrence of delayed VEP latencies in the group with vision problems (56% versus 29%).

Insert Fig 1 about here

Since we used two variants of motion stimuli - translational (linear) and radial ones, we were also interested, whether they somehow differ in abnormality detection. Comparison of the two motion stimuli variants for the whole group (162 eyes) is depicted in Fig 2. In 133 eyes (82%) the results of both motion VEP types correlated – the latencies were both either normal (in 72%), or delayed (in 10%). In 20 eyes (12%) the abnormal latencies were found only to linear motion stimuli and in 9 eyes (6%) only the radial motion VEPs were prolonged.

Insert Fig 2 about here

Fig. 3 shows development of the VEP findings in a particular patient. Upper row of VEPs was recorded before an infusion antibiotic treatment; the lower row was gained one year later. There was distinct prolongation of latencies in all VEP types in the left eye during the first patient's investigation that normalised completely after the antibiotic treatment.

Insert Fig 3 about here

Discussion and Conclusions

Our results have shown that by means of VEPs it is possible to find a distinct delay in information transmission and processing within the visual pathway and cortical areas in patients with verified Neuroborreliosis. The fact, that only 40% of patients showed prolonged latencies of VEPs is not surprising, since pathological processes accompanying NB can but also do not have to affect the optic nerve and visual areas – the clear optic neuritis occurs rather rarely (Rothermel et al., 2001) and there are no reports on particular visual areas dysfunctions. Much more interesting is, however, the fact that if solely reversal VEPs were used, we would uncover only 13% of abnormal VEP findings in our group. This rather low sensitivity of reversal VEPs to CNS dysfunction accompanying NB can probably explain why there are so few literature data on VEPs in NB available, because the pattern-reversal VEPs are predominantly examined in most electrophysiological laboratories. When we, however, additionally used motion stimuli for the VEP acquisition, the prevalence of abnormal findings increased to the mentioned 40%. By means of the stimuli designed in our laboratory (Kremláček et al., 2004) the function of the whole visual motion processing system (i.e. of the magnocellular visual pathway and its continuation through the dorsal stream) seems to be tested quite selectively (Kubová et al., 1995; Kubová and Kuba, 1995; Kubová et al., 1996a, Kubová et al., 1996b; Kubová et al., 1996c; Korth et al., 2000; Schulte-Korne et al., 2004). On contrary, pattern-reversal VEPs (especially those to high contrast and high spatial frequency stimuli) originate mainly in the striate area (Brecelj et al., 1998; Nakamura et al., 2000; Di Russo et al., 2005) and represent activation of the parvocellular pathway and so both types of VEPs might be complementary in visual system testing. Our finding of higher sensitivity of the M-VEPs indicates that the magnocellular pathway or motion processing cortical areas are more affected by NB than the parvocellular pathway and the related part of the striate cortex. We have found similar rather selective involvement of the magnocellular pathway (but not in such a high percentage of cases) in patients with Multiple Sclerosis (Kubová and Kuba, 1992; Kubová and Kuba, 1995). The

pathophysiological reasons for these findings are, however, not clear yet. It is known that the ganglion M-cells within the retina and their axons as well as magnocellular neurons in LGN are larger than neurons of the parvocellular pathway, which might predispose them to damage caused by NB. In addition, the M-VEPs (compared to the pattern-reversal VEPs) test also the function of some other cortical areas besides the striate one (several extrastriate areas including e.g. MT and MST regions (Hollants-Gilhuijs et al., 2000)) and so they may become involved also in defects of higher order brain regions (the probability of M-VEPs delay increases). The variously affected extrastriate areas can also explain the difference in our results regarding the two types of the used M-VEPs to the translation and radial motion. Whilst linear translational motion is mainly processed in area V1 and one subdivision of V5/MT+ area (equivalent of MT area in monkeys), more complex motion (radial, circular and spiral) is detected by another parts of V5/MT+ area (Morrone et al., 1995; Morrone et al., 2000; Ptito et al., 2000). In addition, slow motion is conducted through the striate area (V1) and fast motions through extrastriate ways (possibly superior colliculi or pulvinar) - ffytche et al., 1995 and thus the M-VEPs to our radial stimuli that contain high speed motion (50°/sec) in periphery can be affected in different way than the VEPs to our translational motion (10°/sec).

Logically, we could assume that abnormally prolonged VEP latencies will be present in those patients who reported some subjective visual disorders. However, we have shown that not all patients with visual problems displayed abnormal VEPs (we found only 56% of abnormal VEPs in this group) and on contrary, not all patients with normal vision (**and without past history suggesting visual symptoms**) had normal VEPs (abnormal VEPs were found in 29%). Nevertheless, a similar discrepancy between subjective ophthalmological symptoms and VEP findings is quite common also in Multiple sclerosis and in the recovery phase of acute Optic neuritis (Bynke et al., 1980; Persson and Wanger, 1984; Frederiksen et al., 1996).

It indicates that there does not have to be full correlation between the functional state of the visual pathway (as verified by VEPs) and subjective feelings of patients.

Since in our classification of pathological VEP latencies we have used latency norms with 2.5 standard deviation over the control group mean values (this represents ca 99% confidence interval), there is a low probability of false positive findings in our study and thus the reported proportion of pathological VEPs in NB seems to be significant. Therefore, we recommend using of complex VEP testing as a complementary diagnostic method in patients with suspected (objectively not proved) Neuroborreliosis.

Acknowledgements: Supported by Czech Ministry of Education (VZ 0021620816).

References

- Brecelj J, Kakigi R, Koyama S, Hoshiyama M. Visual evoked magnetic responses to central and peripheral stimulation: simultaneous VEP recordings. *Brain Topogr* 1998;10:227-37.
- Bynke H, Rosèn I, Sandberg-Wollheim. Correlatin of visual potentials, ophthamolgical and neurological findings after unilateral optic neuritis. *Acta Ophthal* 1980;58:673-687.
- Chabot RJ, Sigal LH. QEEG and evoked potentials in central nervous system Lyme disease. *Clin Electroencephalogr* 1995;26:137-45.
- Christova I, Komitova R. Clinical and epidemiological features of Lyme borreliosis in Bulgaria. *Wien Klin Wochenschr* 2004;116:42-6.
- Di Russo F, Pitzalis S, Spitoni G, Aprile T, Patria F, Spinelli D, Hillyard SA. Identification of the neural sources of the pattern-reversal VEP. *Neuroimage* 2005;24:874-86.
- Dupuis MJ. [Multiple neurologic manifestations of *Borrelia burgdorferi* infection] *Rev Neurol (Paris)* 1988;144:765-75.
- ffytche DH, Guy CN, Zeki S. The parallel visual motion inputs into areas V1 and V5 of human cerebral cortex. *Brain* 1995;118:1375-94.

- Frederiksen JL, Petrera J, Larsson HBW, Stingsby B, Olesen J. Serial MRI, VEP, SEP and biotesiometry in acute optic neuritis: value of baseline results to predict the development of new lesion at one year follow up. *Acta Neurol Scand* 1996;93:246-52.
- Göpfert E, Müller R, Markwardt F, Schlykowa L. Visuell evozierte Potentiale bei Musterbewegung. *Z Elektroenzephalogr Elektromyogr* 1983;14:47-51.
- Göpfert E, Schlykowa L, Müller R. Zur Topographie des Bewegungs-VEP am Menschen. *EEG EMG Z Elektroenzephalogr Elektromyogr* 1988;19:14-18.
- Gutierrez MA, de Pablos C, Oterino A, Garcia Monco JC. Isolated posterior cord syndrome in Lyme s disease: a clinical neurophysiological study. *Rev Neurol* 2001;33:954-7.
- Halperin JJ, Luft BJ, Anand AK, Roque CT, Alvarez O, Volkman DJ, Dattwyler RJ. Lyme neuroborreliosis: central nervous system manifestations. *Neurology* 1989;39:753-9.
- Hoffman MB, Bach M. The distinction between eye and object motion is reflected by the motion-onset visual evoked potential. *Exp Brain Res* 2002;144:141-151.
- Hoffmann MB, Unsöld AS, Bach M. Directional tuning of human motion adaptation as reflected by the motion VEP. *Vis Res* 2001;40:2187-2194.
- Hollants-Gilhuijs MA, De Munck JC, Kubová Z, van Royen E, Spekreijse H. The development of hemispheric asymmetry in human motion VEPs. *Vision Res* 2000;40:1-11.
- Kaiser R. Neuroborreliosis. *J Neurol* 1998;245:247-55.
- Karma A, Seppala I, Mikkila H, Kaakkola S, Viljanen M, Tarkkanen A. Diagnosis and clinical characteristics of ocular Lyme borreliosis. *Am J Ophthalmol* 1995;119:127-35.
- Karussis D, Weiner HL, Abramsky O. Multiple sclerosis vs Lyme disease: a case presentation to a discussant and a review of the literature. *Mult Scler* 1999;5:395-402.
- Korth M, Kohl S, Martus P, Sembritzki T. Motion-Evoked pattern visual evoked potentials in glaucoma. *J Glaucoma* 2000;9:376-87.
- Kremláček, J., Kuba, M., Kubová, Z., & Chlubnová, J. Motion-onset VEPs to translating, radial, rotating and spiral stimuli. *Doc Ophthalmol* 2004;109:169–175.
- Kuba M, Kubová Z. Visual evoked potentials specific for motion-onset. *Doc Ophthalmol* 1992;80:83-89.
- Kubová Z, Kuba M, Hrochová J, Svěrák J. Motion-onset visual evoked potentials improve the diagnosis of glaucoma. *Doc Ophthalmol* 1996c;92:211-21.

- Kubová Z, Kuba M, Hubáček J, Vít F. Properties of visual evoked potentials to onset of movement on a television screen. *Doc Ophthalmol* 1990;75:67-72.
- Kubová Z, Kuba M, Juran J, Blakemore C. Is the motion system relatively spared in amblyopia? Evidence from cortical evoked responses. *Vision Res* 1996a;36:181-90.
- Kubová Z, Kuba M, Peregrin J, Nováková V. Visual evoked potential evidence for magnocellular system deficit in dyslexia. *Physiol Res* 1996b;45:87-9.
- Kubová Z, Kuba M, Spekreijse H, Blakemore C. Contrast dependence of motion-onset and pattern-reversal evoked potentials. *Vision Res* 1995;35:197-205.
- Kubová Z, Kuba M. Clinical application of motion-onset visual evoked potentials. *Doc Ophthalmol* 1992;81:209-18.
- Kubová Z, Kuba M. Motion onset VEPs improve the diagnostics of multiple sclerosis and optic neuritis. *Sb Ved Pr Lek Fak Karlovy Univerzity Hradci Kralove Suppl* 1995;38:89-93.
- Lesser RL, Kornmehl EW, Pachner AR, Kattah J, Hedges TR 3rd, Newman NM, Ecker PA, Glassman MI. Neuro-ophthalmologic manifestations of Lyme disease. *Ophthalmology* 1990;97:699-706.
- McDonald WI, Compston A, Edan G, Goodkin D, Hartung HP, Lublin FD, McFarland HF, Paty DW, Polman CH, Reingold SC, Sandberg-Wollheim M, Sibley W, Thompson A, van den Noort S, Weinschenker BY, Wolinsky JS. Recommended diagnostic criteria for multiple sclerosis: guidelines from the International Panel on the diagnosis of multiple sclerosis. *Ann Neurol* 2001;50:121-7.
- Morrone MC, Burr DC, Vaina LM. Two stages of visual processing for radial and circular motion. *Nature* 1995;376:507-9.
- Morrone MC, Tosetti M, Montanaro D, Fiorentini A, Cioni G, Burr DC. A cortical area that responds specifically to optic flow, revealed by fMRI. *Nat Neurosci* 2000;3:1322-8.
- Müller R, Göpfert E, Leineweber M and Greenlee MW. Effect of adaptation direction on the motion VEP and perceived speed of drifting gratings. *Vis Res* 2004;44:2381-2392.
- Nakamura M, Kakigi R, Okusa T, Hoshiyama M, Watanabe K. Effects of check size on pattern reversal visual evoked magnetic field and potential. *Brain Res* 2000;872:77-86.
- Oschmann P, Dorndorf W, Hornig C, Schäfer C, Wellensiek H J, Pflughaupt K W. Stages and syndromes of neuroborreliosis. *J Neurol* 1998;245:262-272.
- Pal E, Barta Z, Nagy F, Wagner M, Vecsei L. Neuroborreliosis in county Baranya, Hungary. *Funct Neurol* 1998;13:37-46.

- Persson HE, Wanger P. Pattern-reversal electroretinograms and visual evoked cortical potentials in multiple sclerosis. *Br J Ophthalmol* 1984;68:760-764.
- Priem S, Munkelt K, Franz JK, Schneider U, Werner T, Burmester GR, Krause A. Epidemiology and therapy of Lyme arthritis and other manifestations of Lyme borreliosis in Germany: results of a nation-wide survey. *Z Rheumatol* 2003;62:450-8.
- Ptito M, Kupers R, Faubert J, Gjedde A. Cortical representation of inward and outward radial motion in man. *Neuroimage* 2001;14:1409-15.
- Rothermel H, Hedges TR 3rd, Steere AC. Optic neuropathy in children with Lyme disease. *Pediatrics* 2001;108:477-81.
- Schneider RK, Robinson MJ, Levenson JL. Psychiatric presentations of non-HIV infectious diseases. Neurocysticercosis, Lyme disease, and pediatric autoimmune neuropsychiatric disorder associated with streptococcal infection. *Psychiatr Clin North Am* 2002;25:1-16.
- Schulte-Körne G, Bartling J, Deimel W, Remschmidt H. Motion-onset VEPs in dyslexia. Evidence for visual perceptual deficit. *Neuroreport* 2004;15:1075-1078.
- Trojano M, Paolicelli D. The differential diagnosis of multiple sclerosis: classification and clinical features of relapsing and progressive neurological syndromes. *Neurol Sci* 2001;22:S98-102.
- Wilske B, Zöller L, Brade V, Eiffert M, Göbel UB, Stanek G, Pfister HW. MIQ 12 Lyme-Borreliose. In Mauch H, Lütticken R, editors. *Qualitätsstandards in der mikrobiologisch-infektiologischen Diagnostik*. Munich: Urban & Fischer Verlag, 2000:1-59.

Tab. 1: Latency group mean values of the main VEP peaks in healthy subjects (n=47, age 19-60) and upper limits of norms (mean + 2.5 SD).

Type of stimulus	Latency of relevant peak (mean value and SD)	Upper limit of norm (M+2.5 SD)
Pattern-reversal VEP (40')	111±5.2 ms	123 ms
Pattern-reversal VEP (20')	114±6.8 ms	131 ms
Pattern-reversal VEP (10')	124±11.0 ms	152 ms
Linear motion-onset VEP	173±11.4 ms	202 ms
Radial motion-onset VEP	169±11.0 ms	197 ms

Legend to Figures:

Fig. 1

Part A - VEP findings in patients with confirmed Neuroborreliosis

Parts B, C - comparison of VEP findings in patients who reported subjective vision problems (C) with the VEP findings in patients who had no vision problems (D).

Segments that represent abnormal motion-onset VEPs are pulled out from the chart.

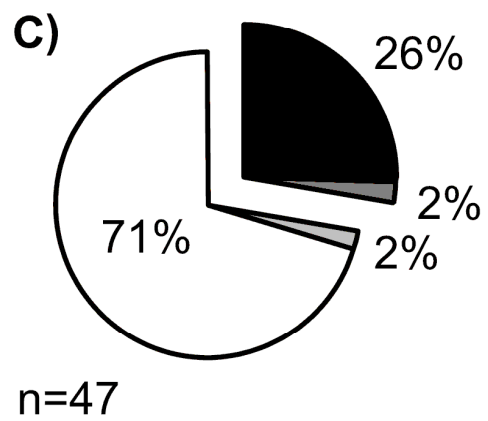
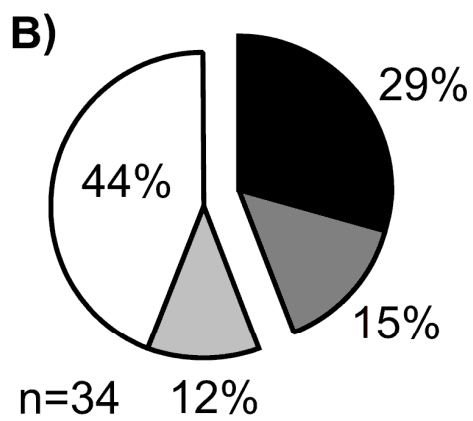
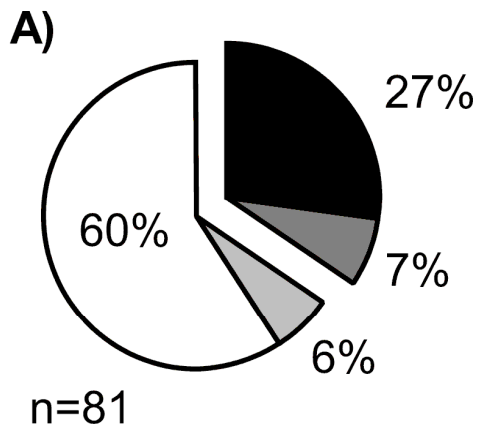
Fig. 2

Latencies of monocular motion-onset VEPs to translation motion are plotted against latencies of monocular motion-onset VEPs to radial motion. The dashed lines show the upper limits of the normal latencies that were acquired as control group means plus 2.5 SD.

Fig. 3

An example of VEP findings in a patient with Neuroborreliosis (woman, 49 years old). Left column of VEPs was obtained prior to an infusion antibiotic treatment, right column one year later. Arrows point to abnormally delayed peaks in VEPs.

Fig. 1



□ Normal PREPs and M-VEPs
▒ Abnormal only PREPs

▒ Abnormal PREPs and M-VEPs
■ Abnormal only M-VEPs

Fig. 2

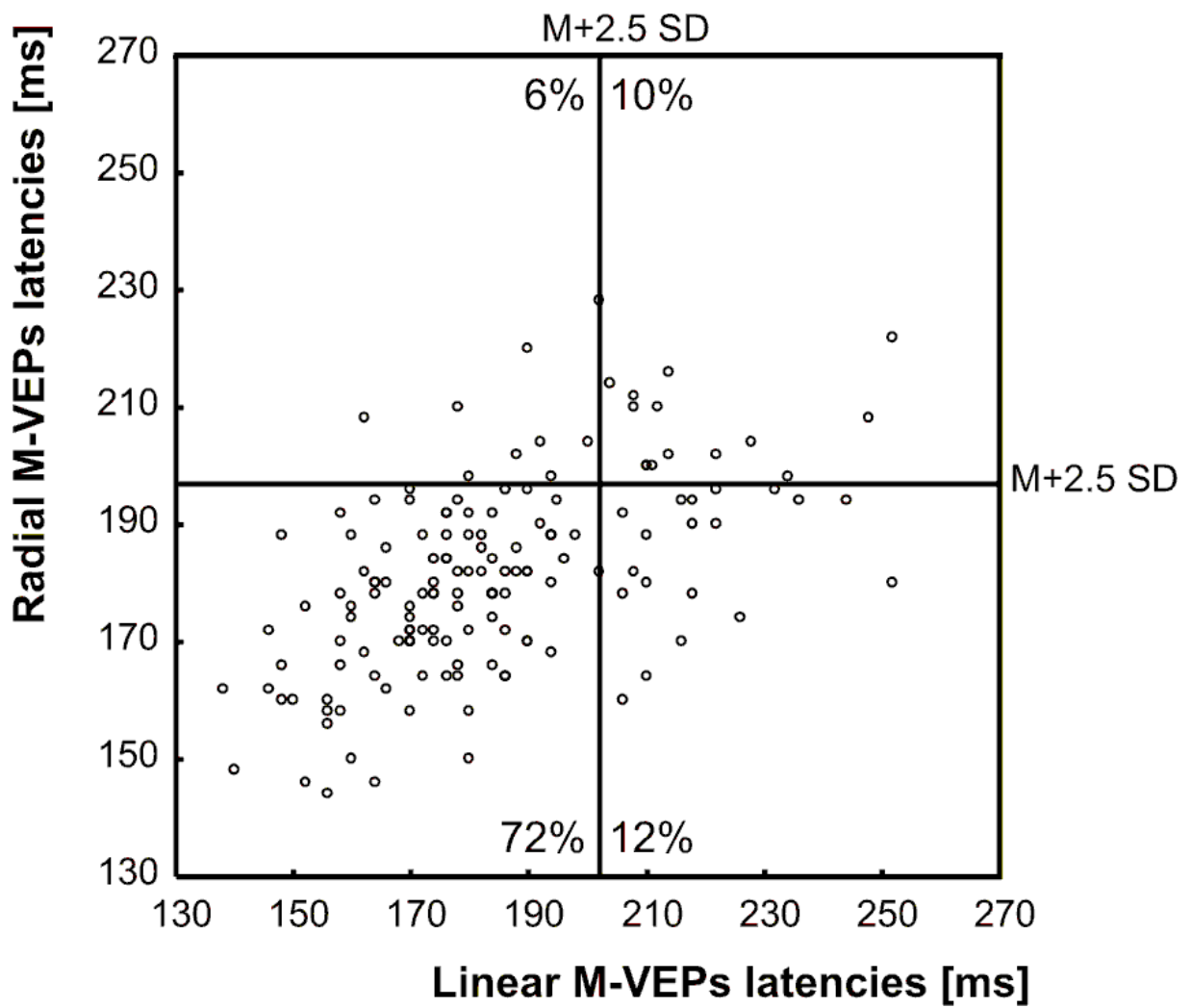


Fig. 3

